



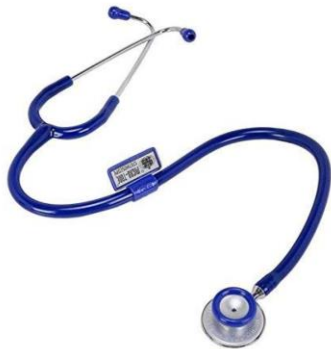TAMIL NADU VETERINARY AND ANIMAL SCIENCES UNIVERSITY
.....Towards excellence

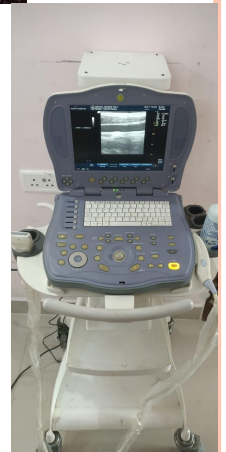
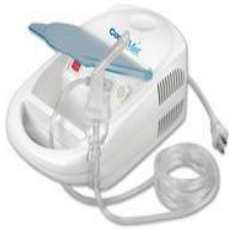
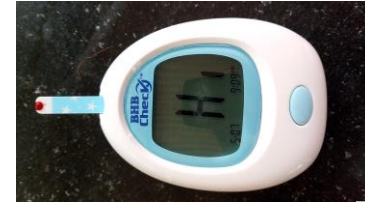
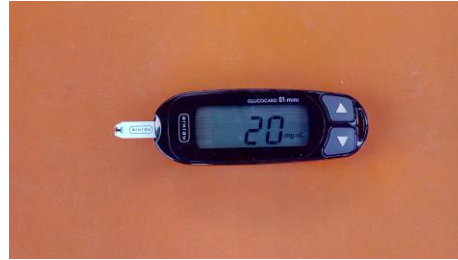
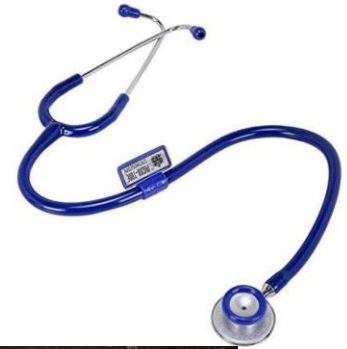CLINICAL UTILITY OF GADGETS IN LARGE ANIMAL PRACTICE

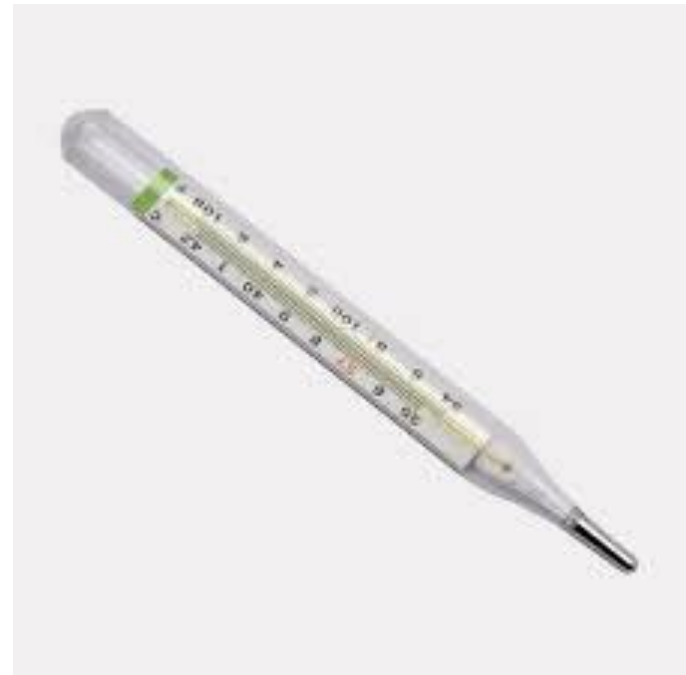By

Dr.S.Sivaraman M.V.Sc.,Ph.D
Faculty of Veterinary Clinical
Medicine, VC &RI, Namakkal
TANUVAS . INDIA





THERMOMETER



Dr.S.Sivaraman



Temperature



- Viral diseases
- Blood protozoan diseases
- Inflammatory Causes
- Bacterial Diseases
- Toxemia or septicemia



VIRAL

- E fever
- FMD
- LSD
- MCF
- IBRT



Protozoan diseases

- Anaplasmosis
- Theileriosis
- Babesiosis
- Trypanosomiasis

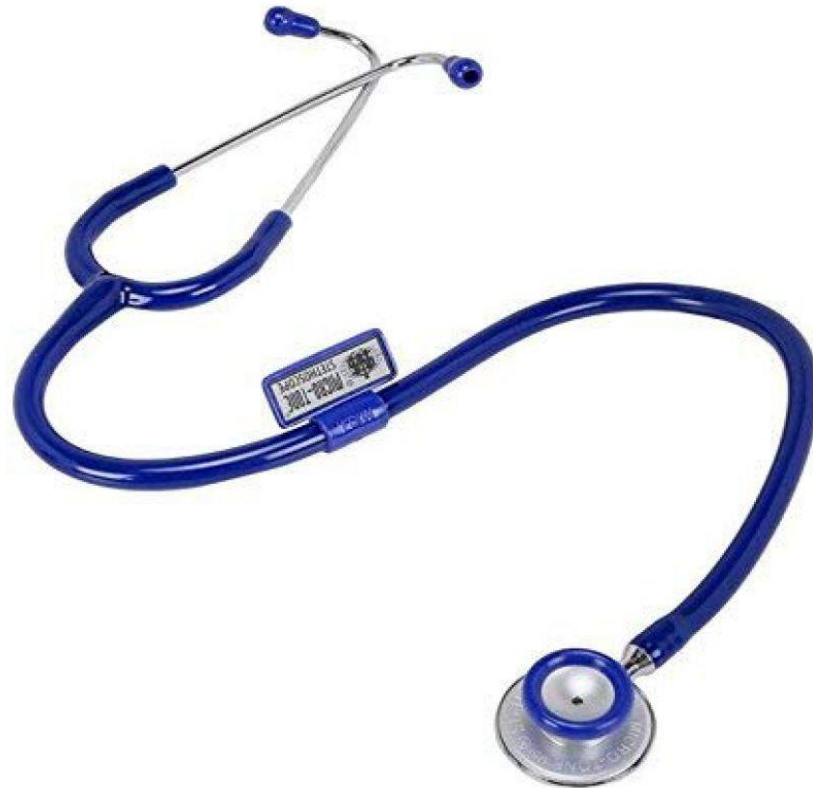

BACTERIAL

- Hemorrhagic septicemia
- Black Quarter



STETHOSCOPE

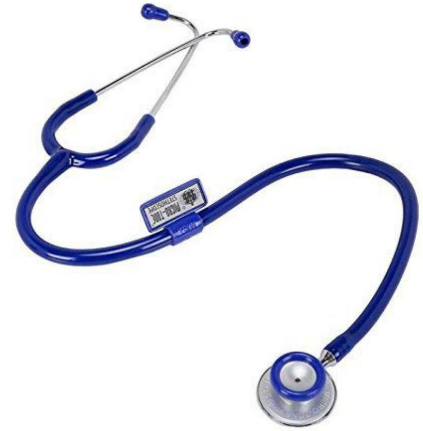

Dr.S.Sivaraman

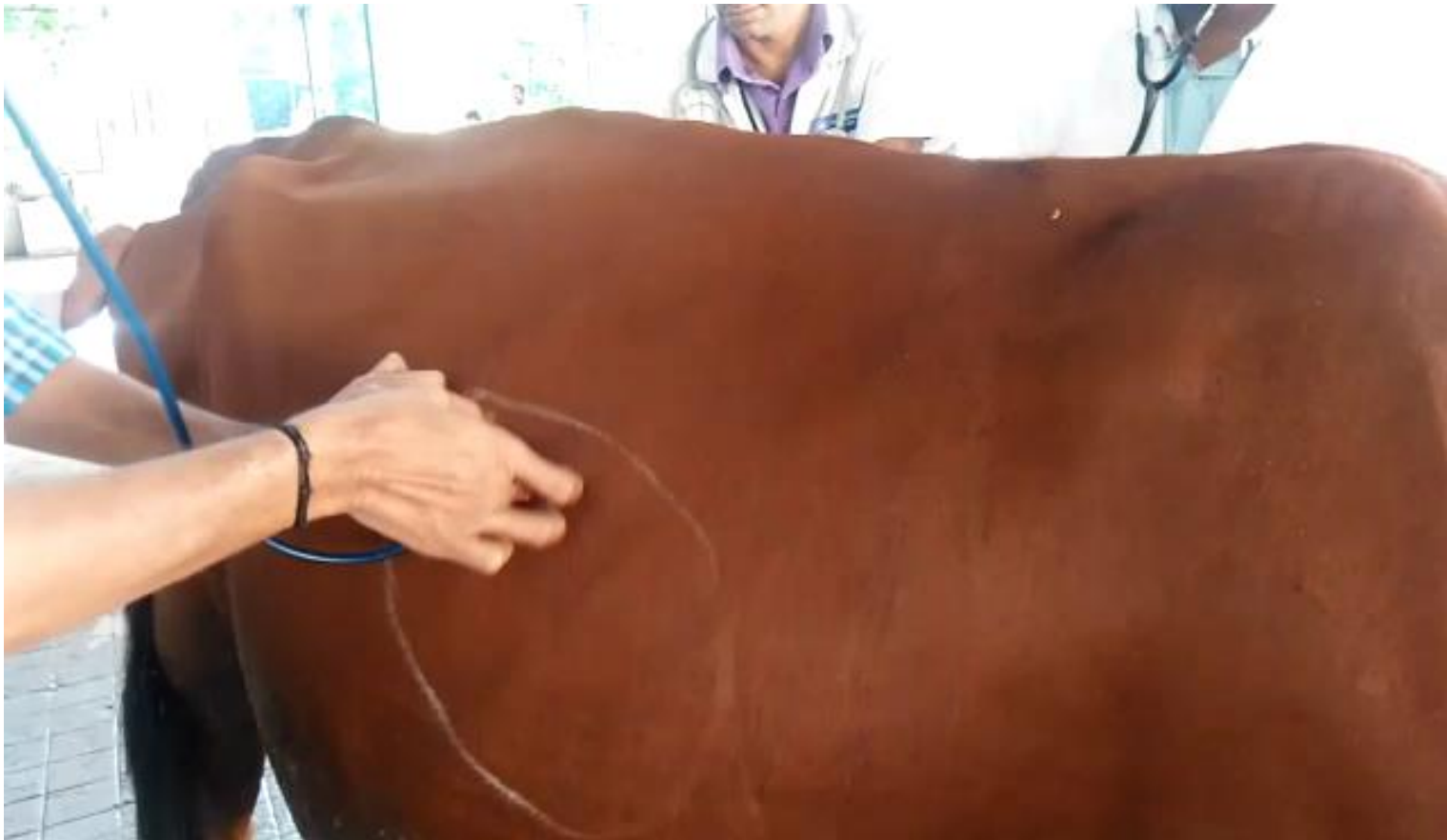

AUSCULTATION OF

- Heart
- Lungs
- Reticulum
- Displacement of Abomasum




PING SOUND



Dr.S.Sivaraman



PH PAPER




Dr.S.Sivaraman

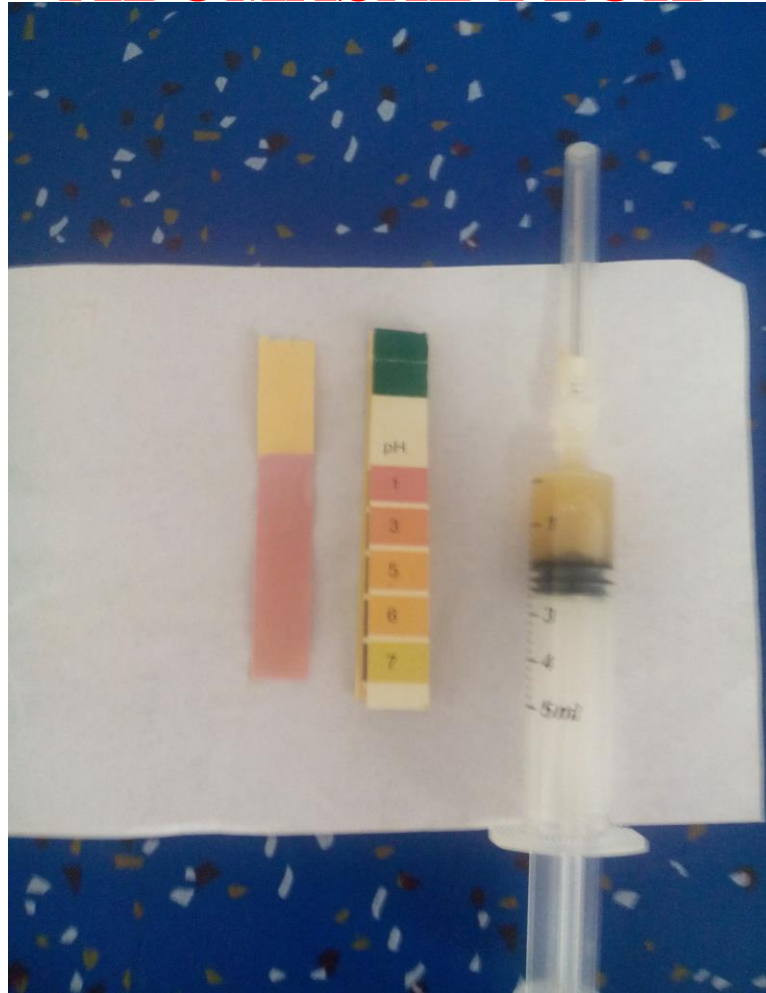


TO ACCESS PH. OF

- Rumen Fluid
- Abomasal Fluid
- Peritoneal fluid
- Urine



ABOMASAL FLUID



Dr.S.Sivaraman



EVALUATION OF URINE PH TO PREDICT CALCIUM STATUS

DCAD	Urine pH	Dry Cow Acid-Base status	Lactating Cow Calcium status
Positive (>mEq/100 g)	7.0 to 8.0	Alkalosis	Low Ca
Negative (< mEq/100 g)	5.5 to 6.5	Mild Metabolic Acidosis	Normal Ca level
Negative (< mEq/100 g)	Below 5.5	Kidney overload	Normal Ca level

- Anionic salts acidify –increases absorption of Ca
- Anionic salts Prevents Milk fever




- Generally acidification occurs after 36 hrs of administration.
- Ammonium chloride 100gm/cow /day – 21 days before calving orally.
- Magnesium chloride – 150gm
- Magnesium sulphate – 150 gm
- **Buffers must not be used in anionic salt rations as it will counter the effect of DCAD**

Dr.S.Sivaraman



URINALYSIS STRIP



Dr.S.Sivaraman



SEALED FOR
YOUR PROTECTION 2881



Ketostix[®]
Reagent Strips
for Urinalysis

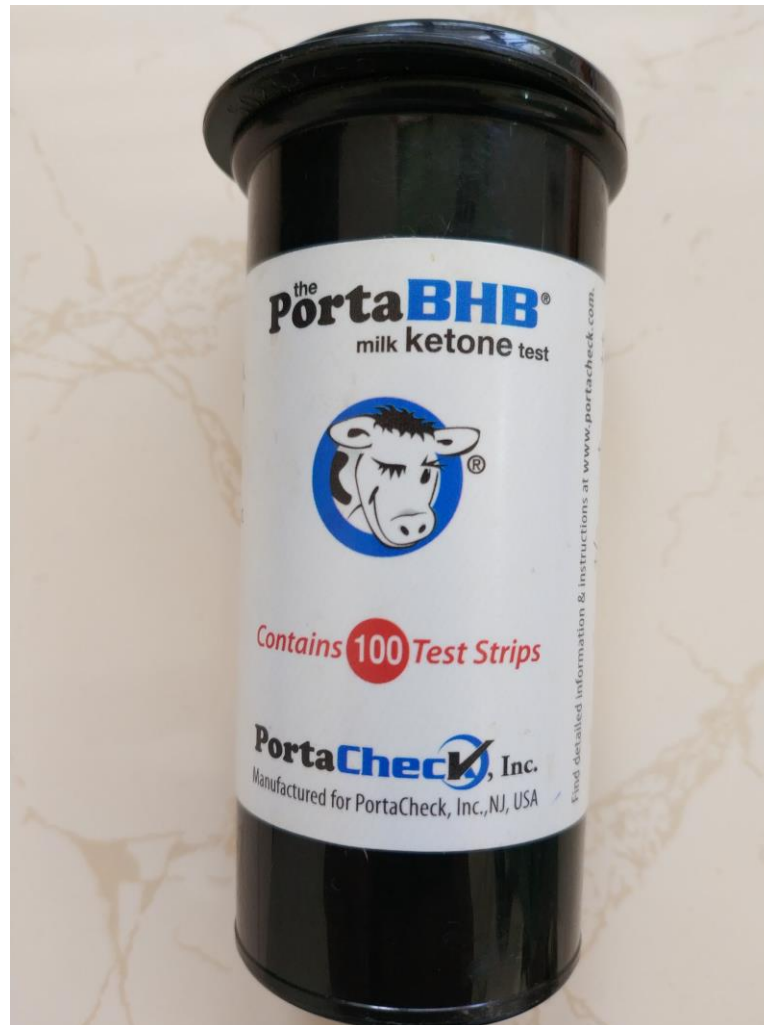Ketone (Acetoacetic
Acid)

For
In Vitro
Diagnostic Use

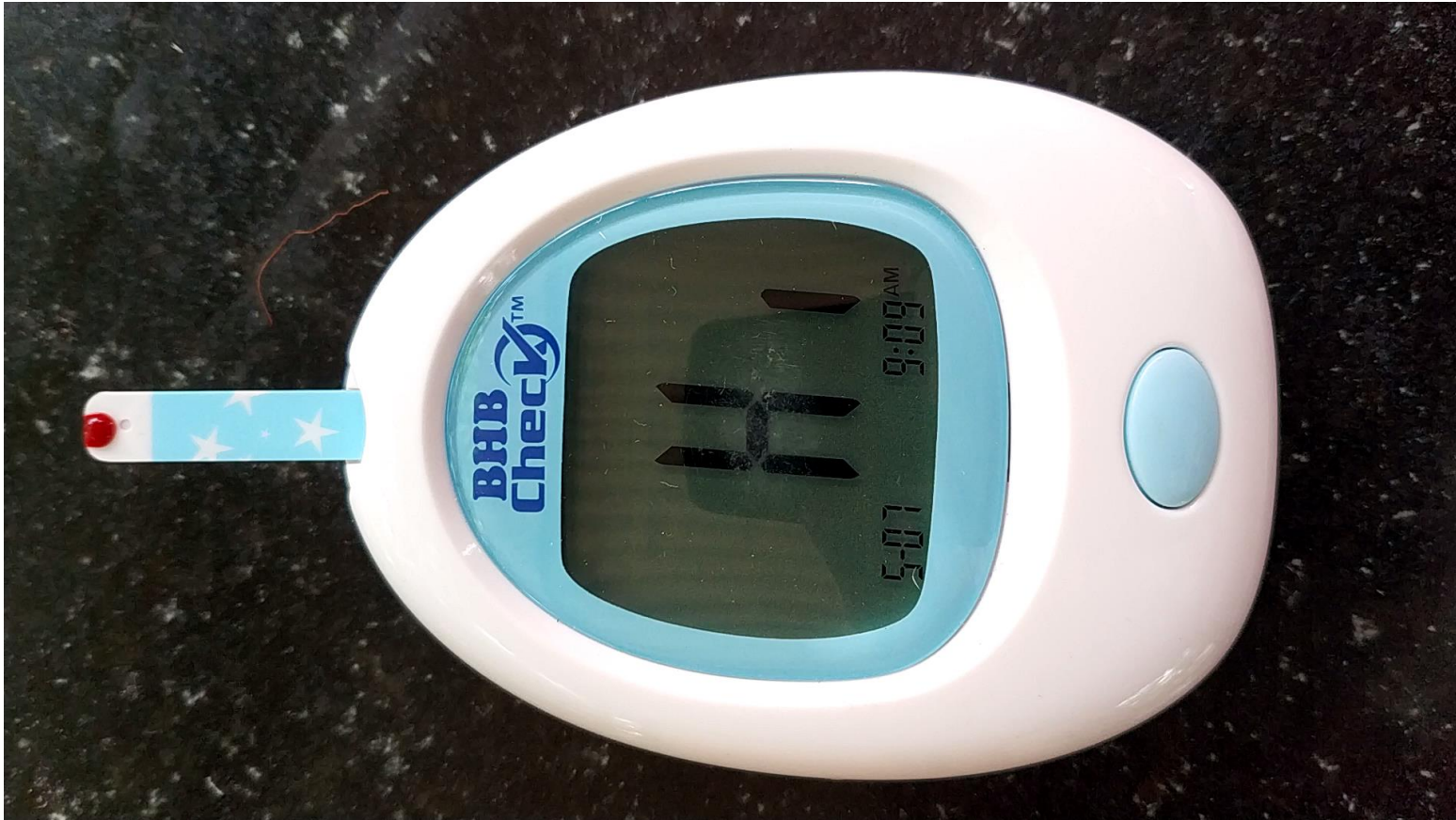
100 Strips



BHB STRIP



KETOMETER



Dr.S.Sivaraman



KETOMETER



Dr.S.Sivaraman



INTERPRETATION OF KETOMETER

- Below 10.4 – Normal
- Above 10.4 to 14.6 mg/dl – Subclinical
- Above 14.6 mg/dl – **Clinical**
- Plasma/serum BHB level



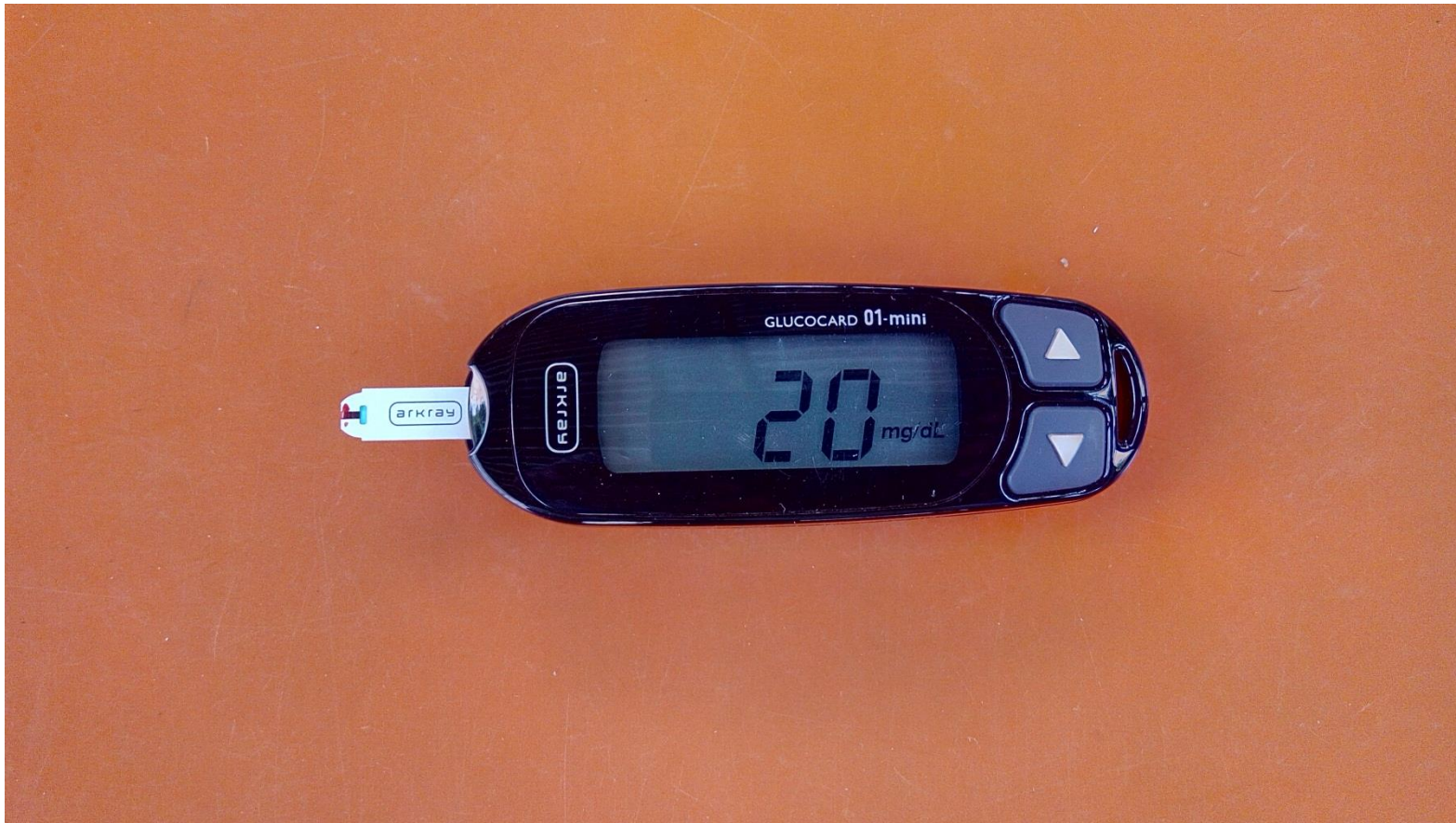GLUCOMETER



Dr.S.Sivaraman



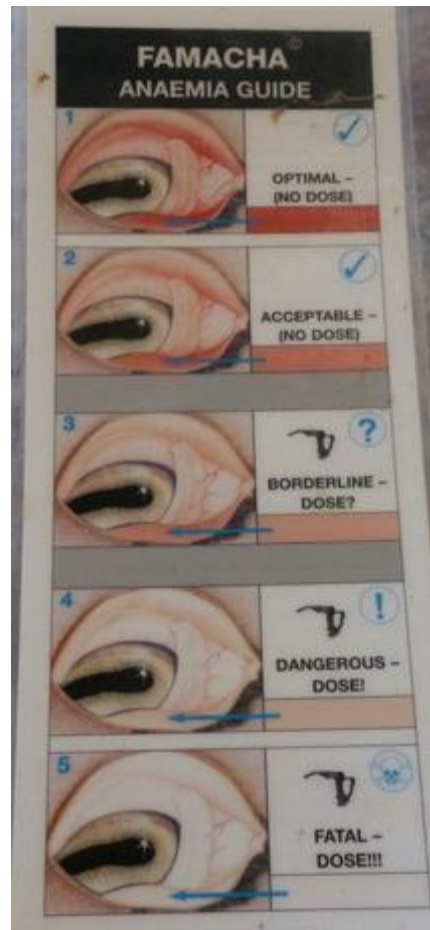
GLUCOMETER



Dr.S.Sivaraman

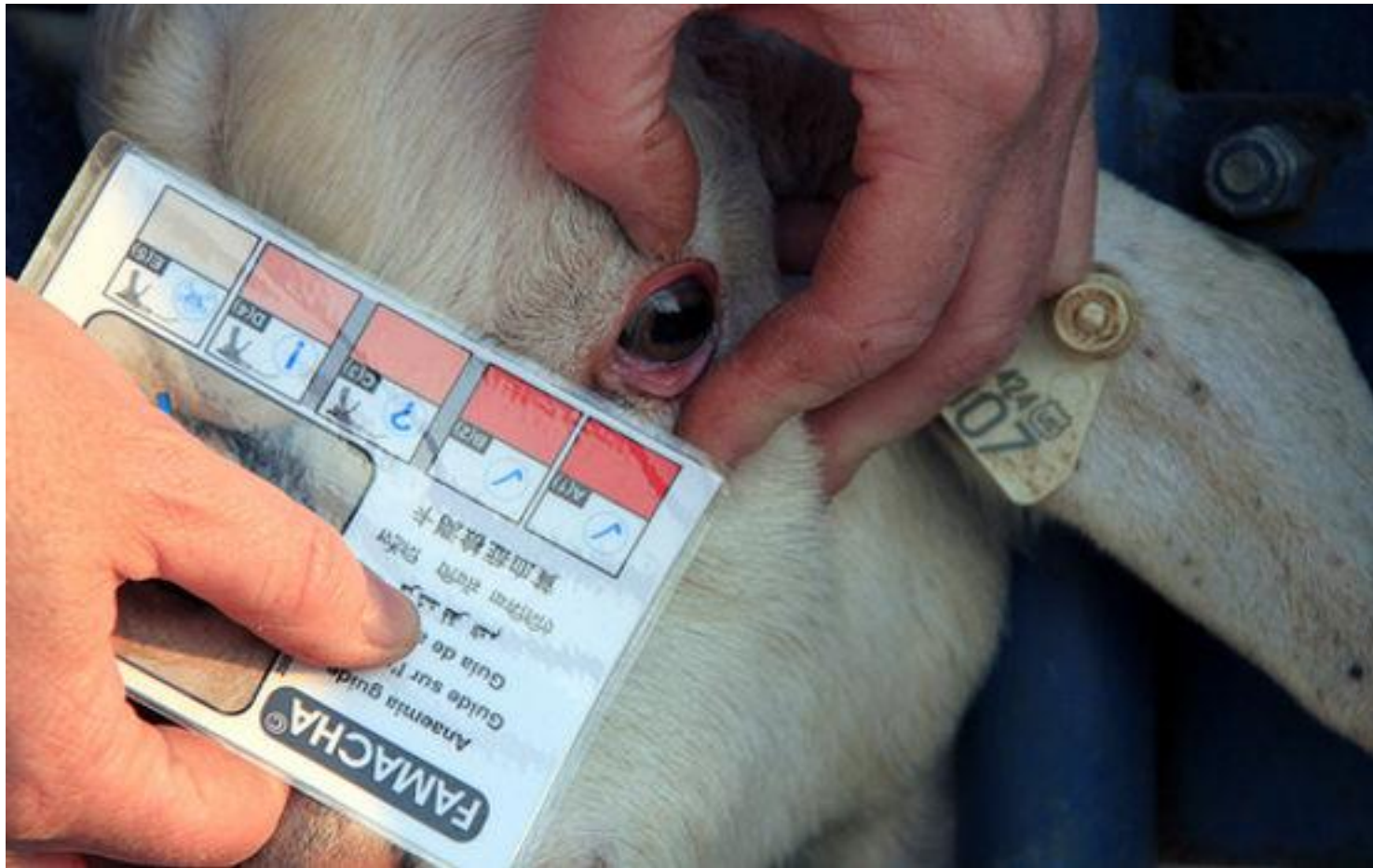

FAMACHA CHART



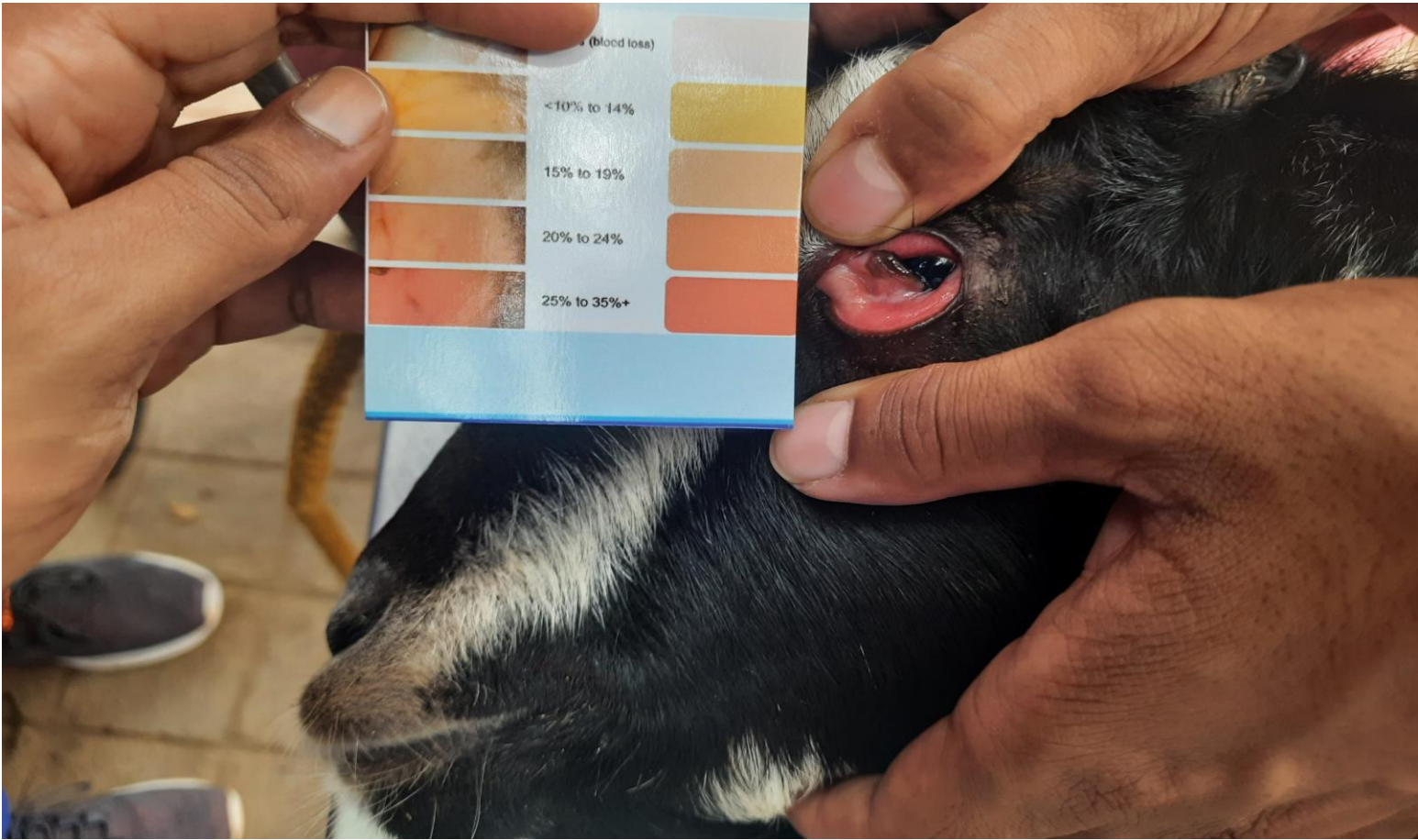
Dr.S.Sivaraman





Dr.S.Sivaraman

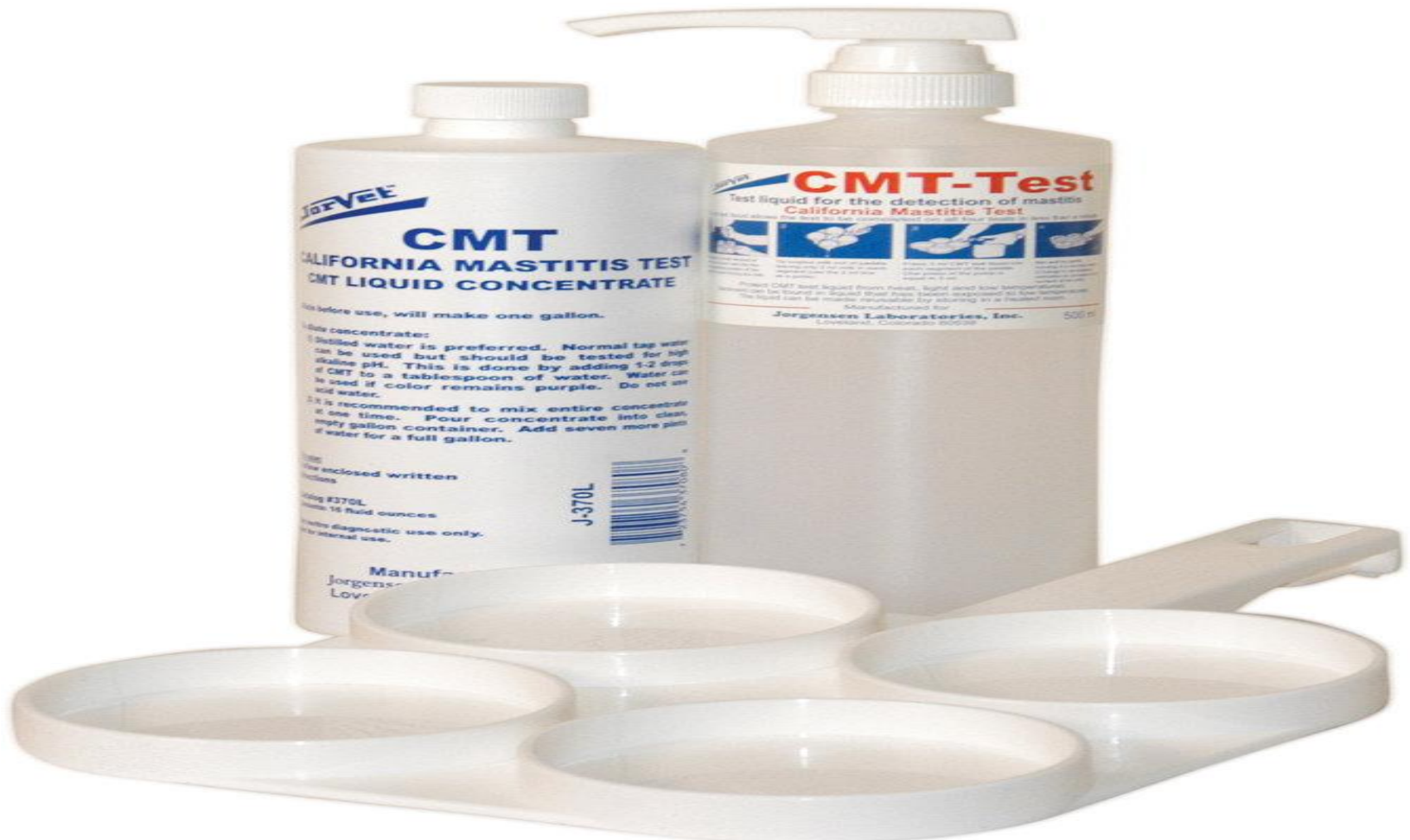



Dr.S.Sivaraman



SUB CLINICAL MASTITIS –CMT TEST



Dr.S.Sivaraman



STOMACH TUBE /RUMEN PUMP



Dr.S.Sivaraman

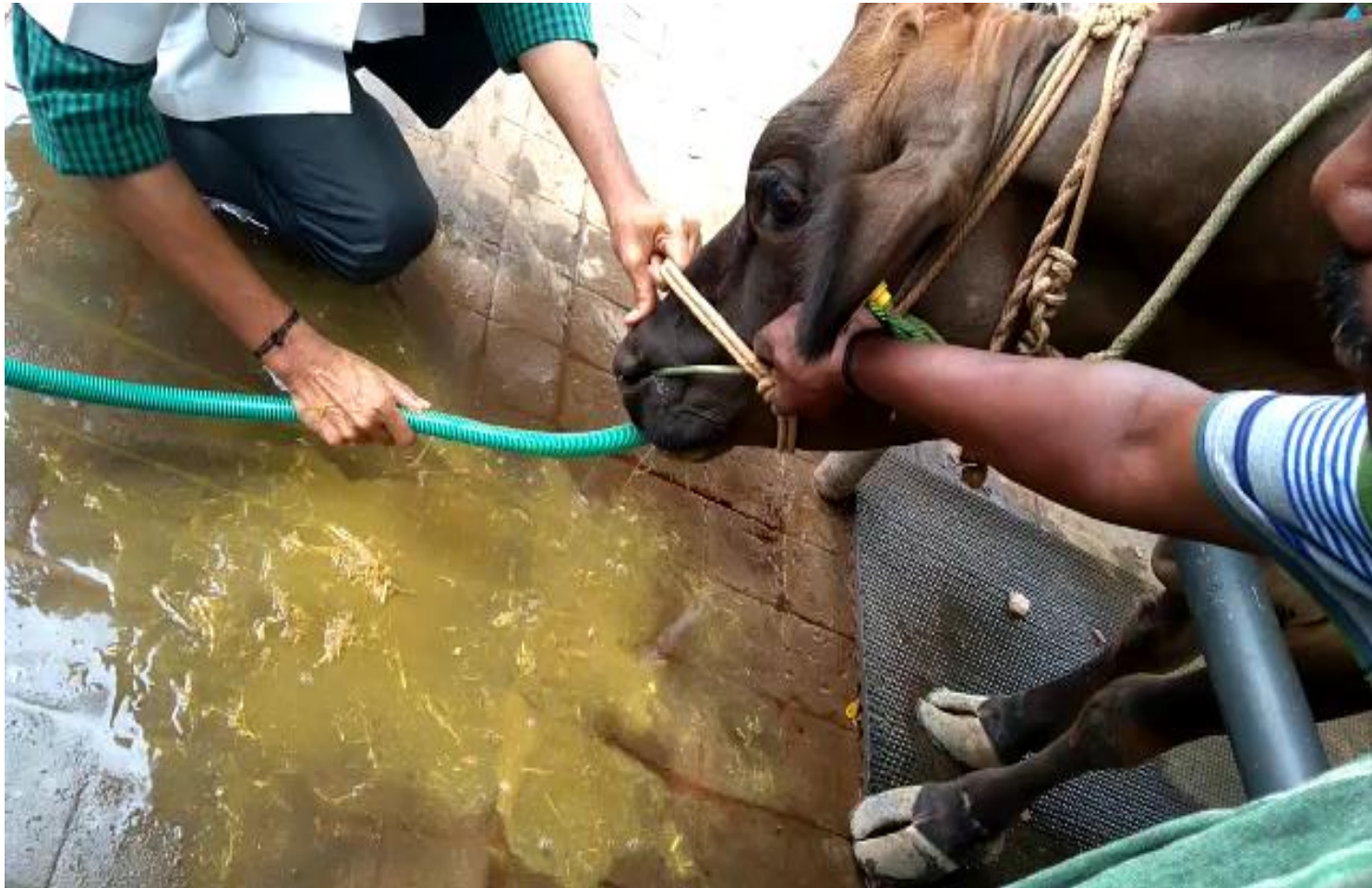

MOUTH GAGS FOR STOMACH TUBE INTUBATION



Dr.S.Sivaraman





Dr.S.Sivaraman



STOMACH TUBE FOR SHEEP & GOATS



Dr.S.Sivaraman



STOMACH TUBE FOR SHEEP & GOATS



Dr.S.Sivaraman

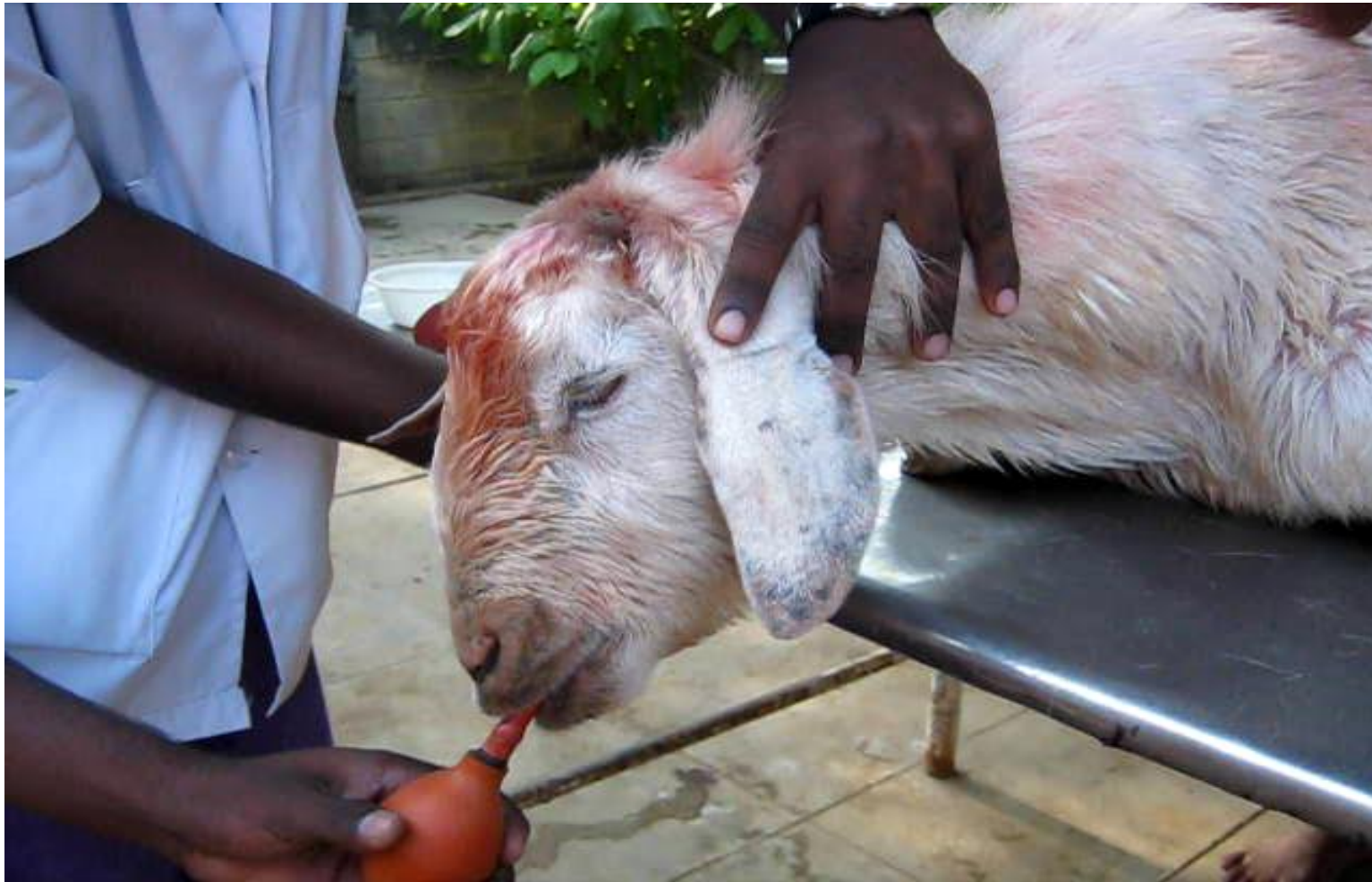



Dr.S.Sivaraman



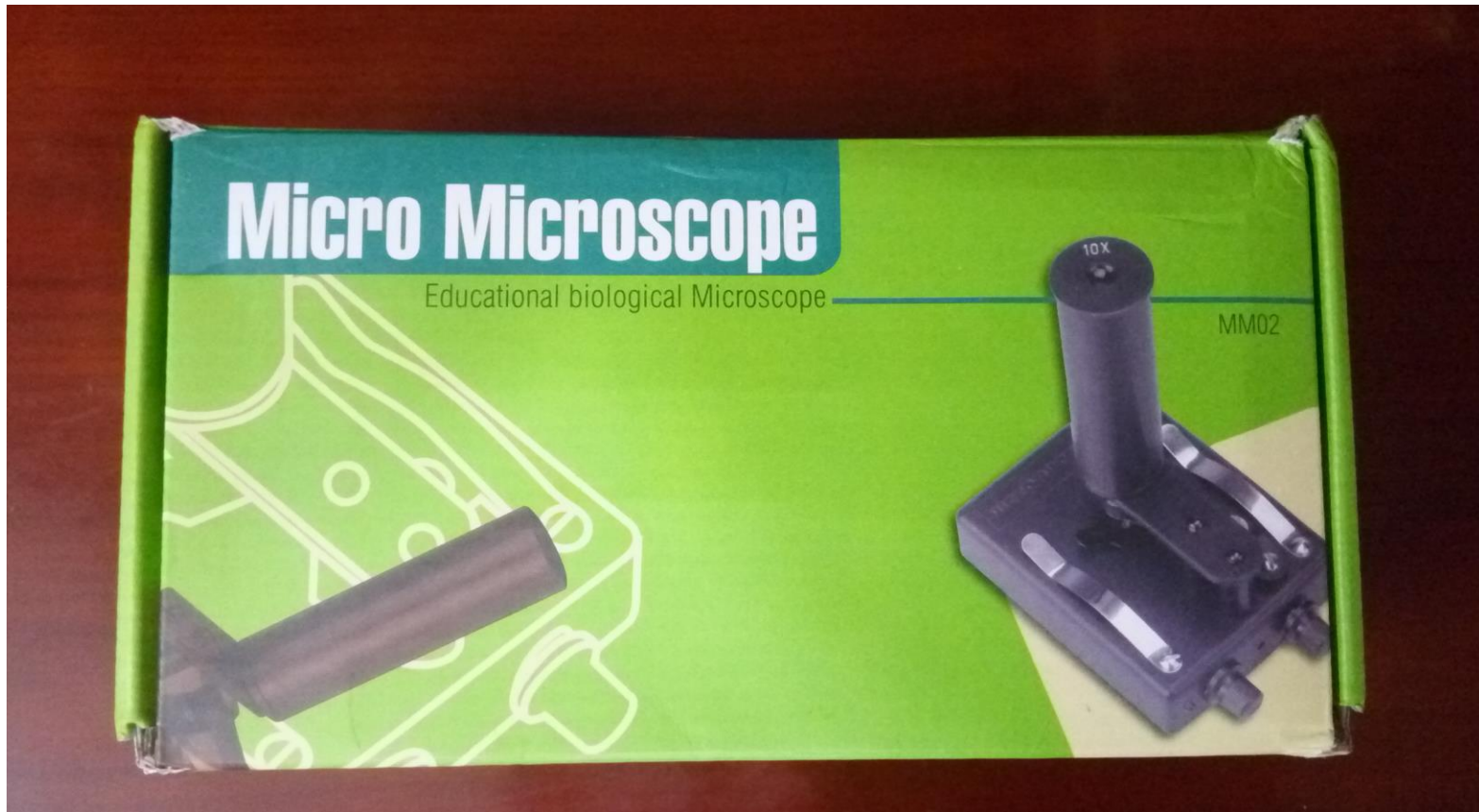STOMACH TUBE FOR SHEEP & GOATS



Dr.S.Sivaraman



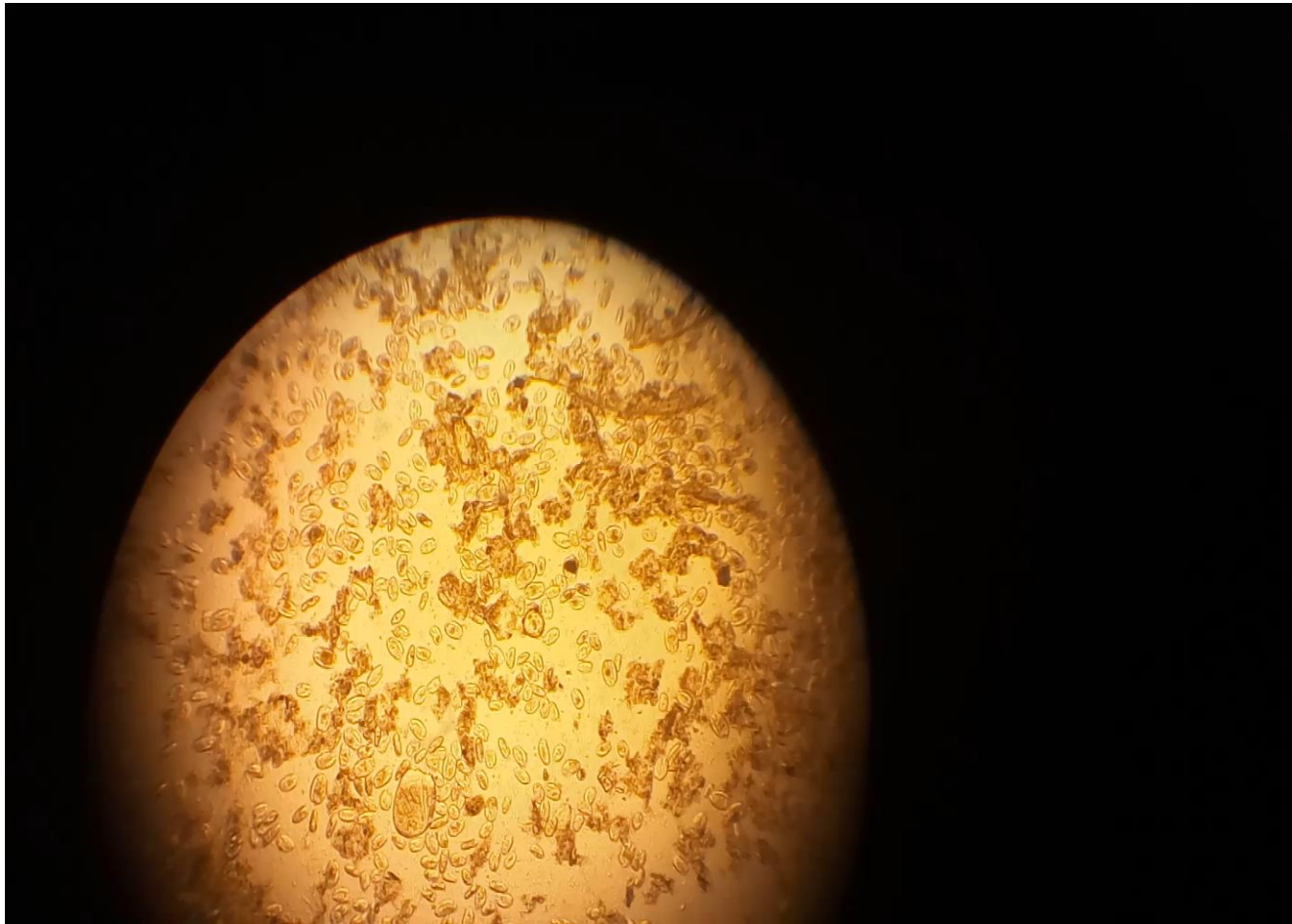
MICRO MICROSCOPE



Dr.S.Sivaraman



RUMEN PROTOZOA



Dr.S.Sivaraman




DIGITAL MICROSCOPE



Dr.S.Sivaraman

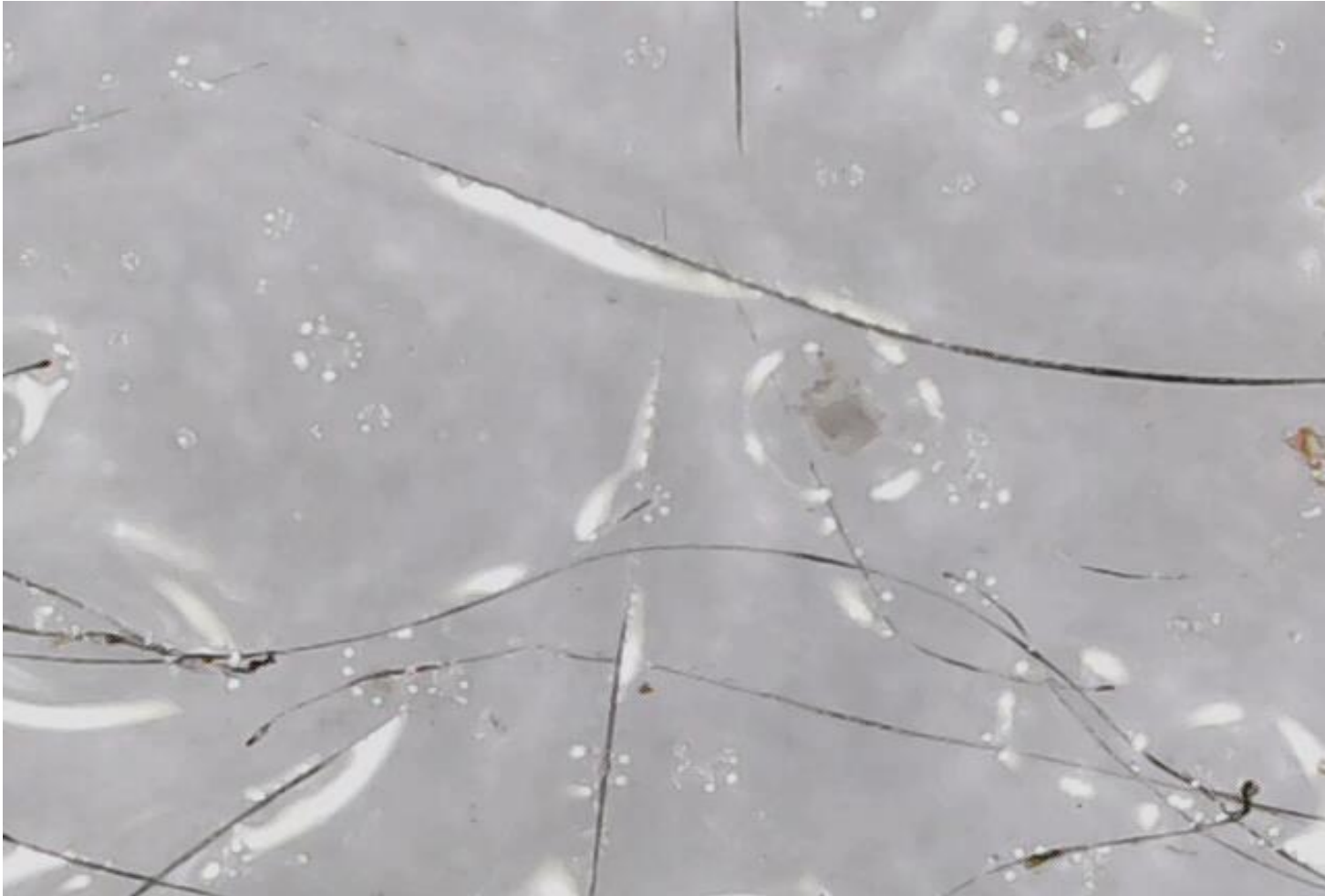



Dr.S.Sivaraman



SKIN SCRAPPING



Dr.S.Sivaraman



RUMEN FLUID- PROTOZOA



Dr.S.Sivaraman



MOUTH GAG



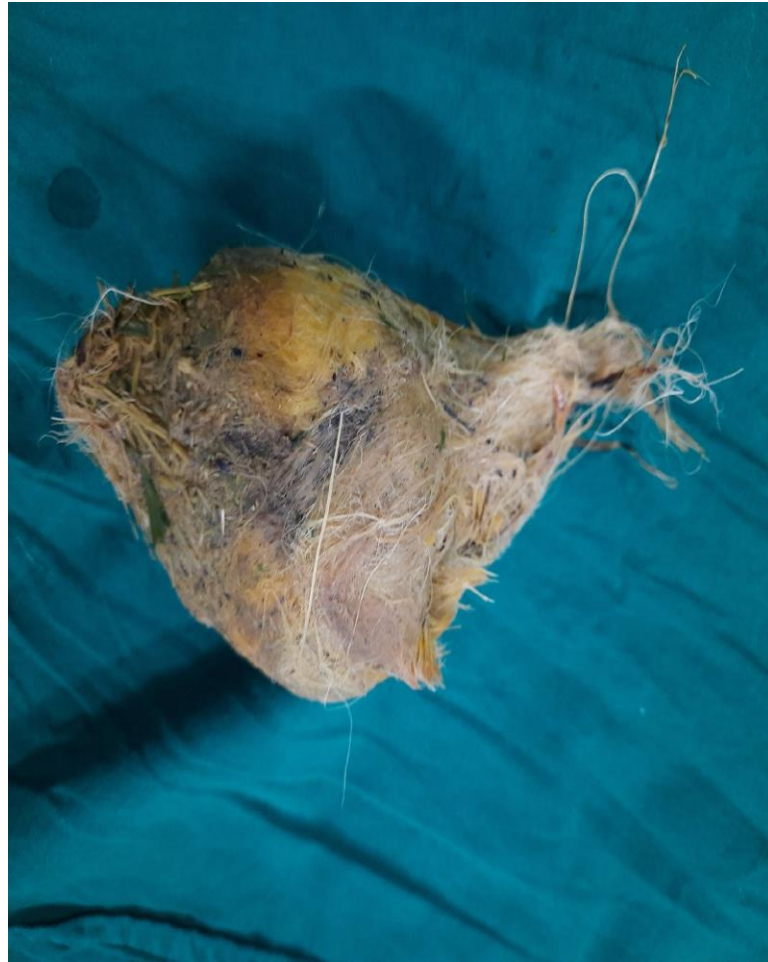GUNTHER'S MOUTH GAG



Dr.S.Sivaraman







Dr.S.Sivaraman



TROCAR AND CANULA



Dr.S.Sivaraman



BRIX REFRACTOMETER

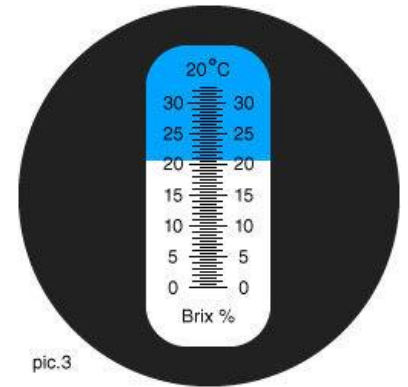


Dr.S.Sivaraman



- Used to measure IgG immunoglobulin in the colostrum

- Brix value $\geq 22\%$ - **should be used**



- Brix value of $< 18\%$ - **should be discarded**

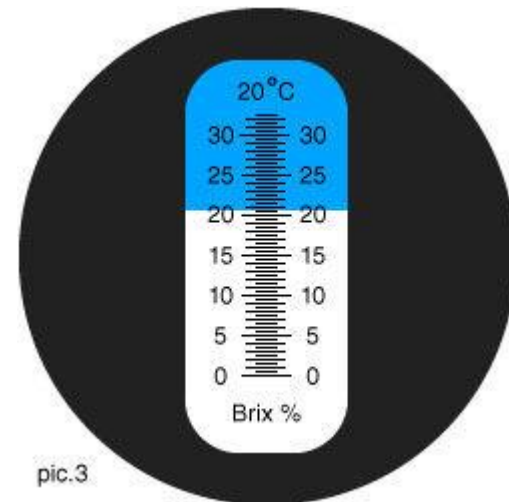
- Brix value of $\geq 18\%$ but $< 22\%$ supplementation should be considered

Dr.S.Sivaraman



IMMUNOGLOBULIN IN CALF SERUM

- Brix refractometer score $> 10\%$
- successful transfer of passive immunity.



pic.3

Dr.S.Sivaraman



RAPID IV INFUSION SET



Dr.S.Sivaraman





Dr.S.Sivaraman



- Normal saline
- DNS
- RL

- **Not Indicated fluids**

- Calcium
- Potassium
- Dextrose 20 %
- Magnesium



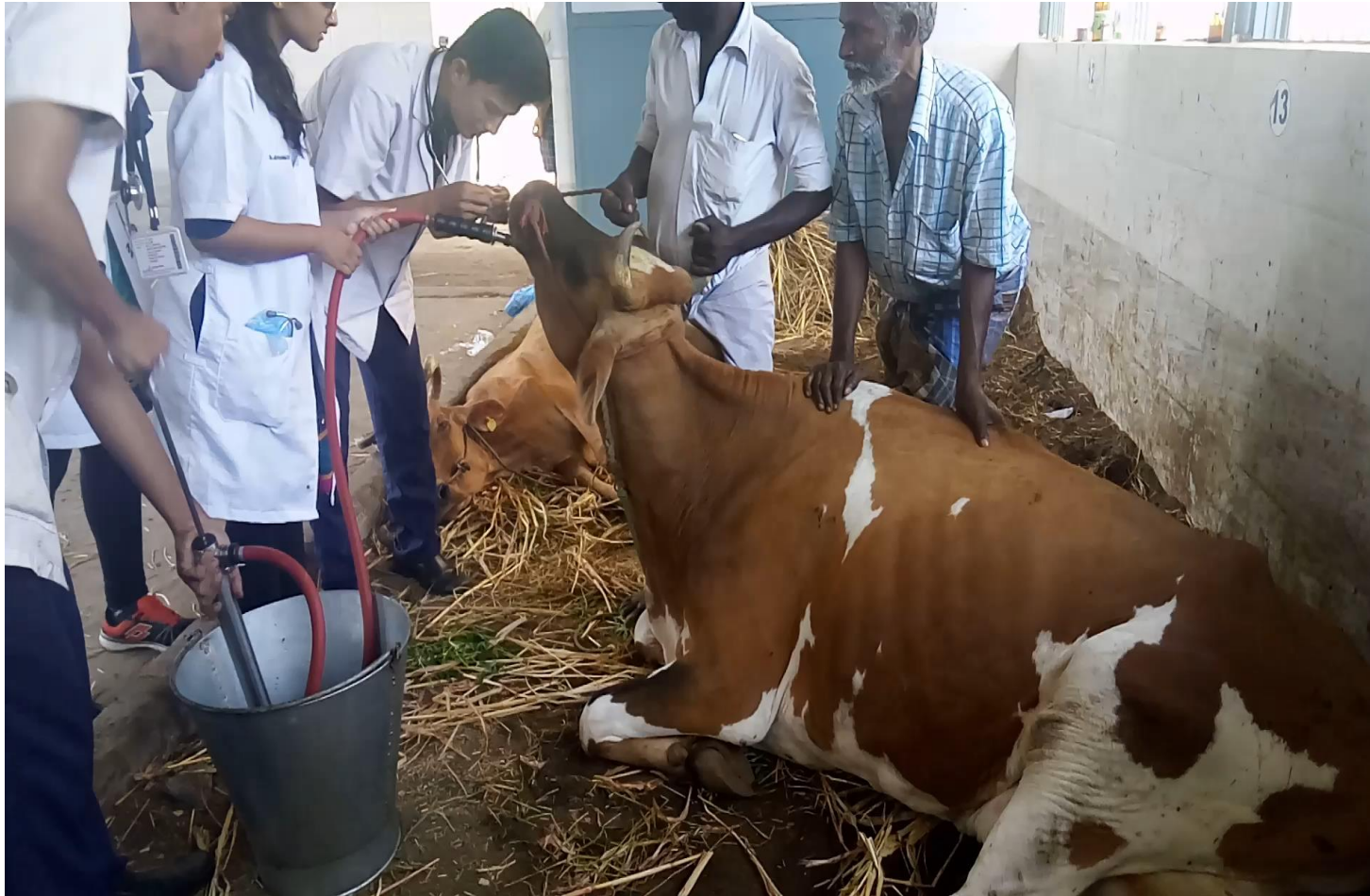ORAL INFUSION PUMP



Dr.S.Sivaraman



ORS - ORAL REHYDRATION PUMP



Dr.S.Sivaraman



ORAL INFUSION PUMP



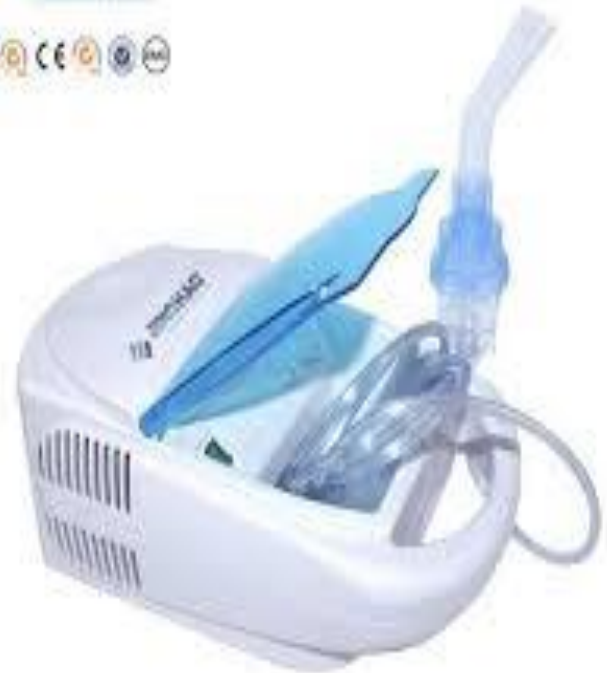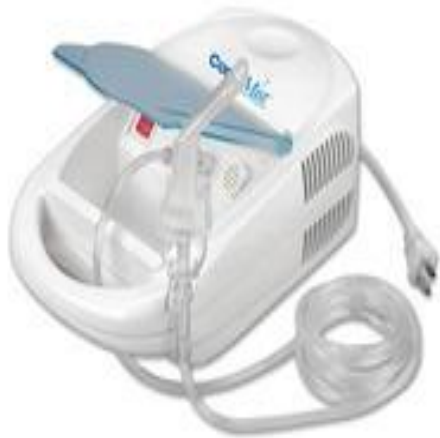Dr.S.Sivaraman



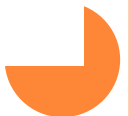- Purgatives
- Electrolyte solutions
- Electrolytes for Alert Downer cows



NEBULIZERS



Dr.S.Sivaraman





Dr.S.Sivaraman



NEBULIZERS

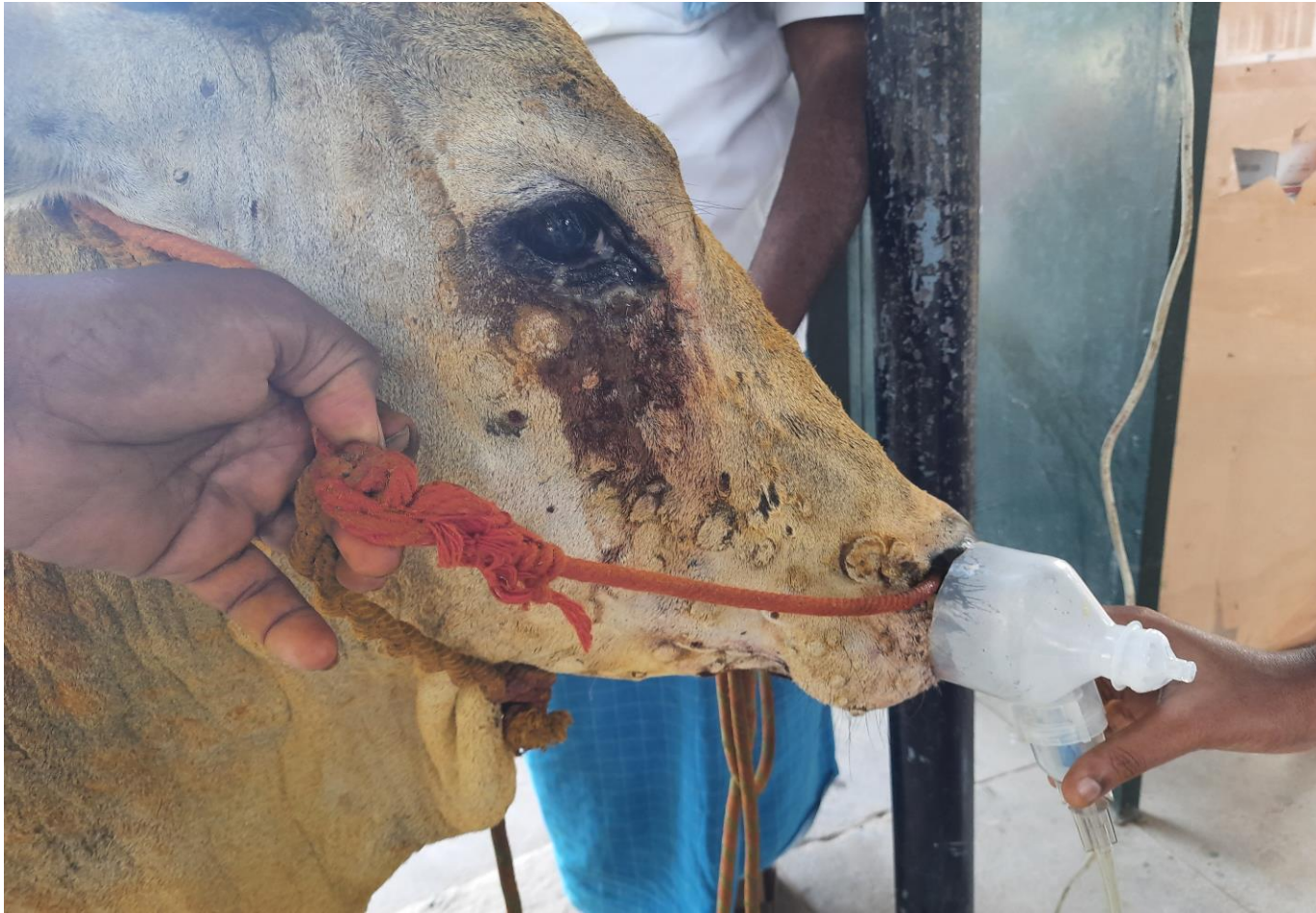- Budesonide
- Antibiotics





Dr.S.Sivaraman





Dr.S.Sivaraman



HYPODERMIC NEEDLE 16' 18'



Dr.S.Sivaraman



ABDOMINOCENTESIS




Dr.S.Sivaraman

Abdominocentesis



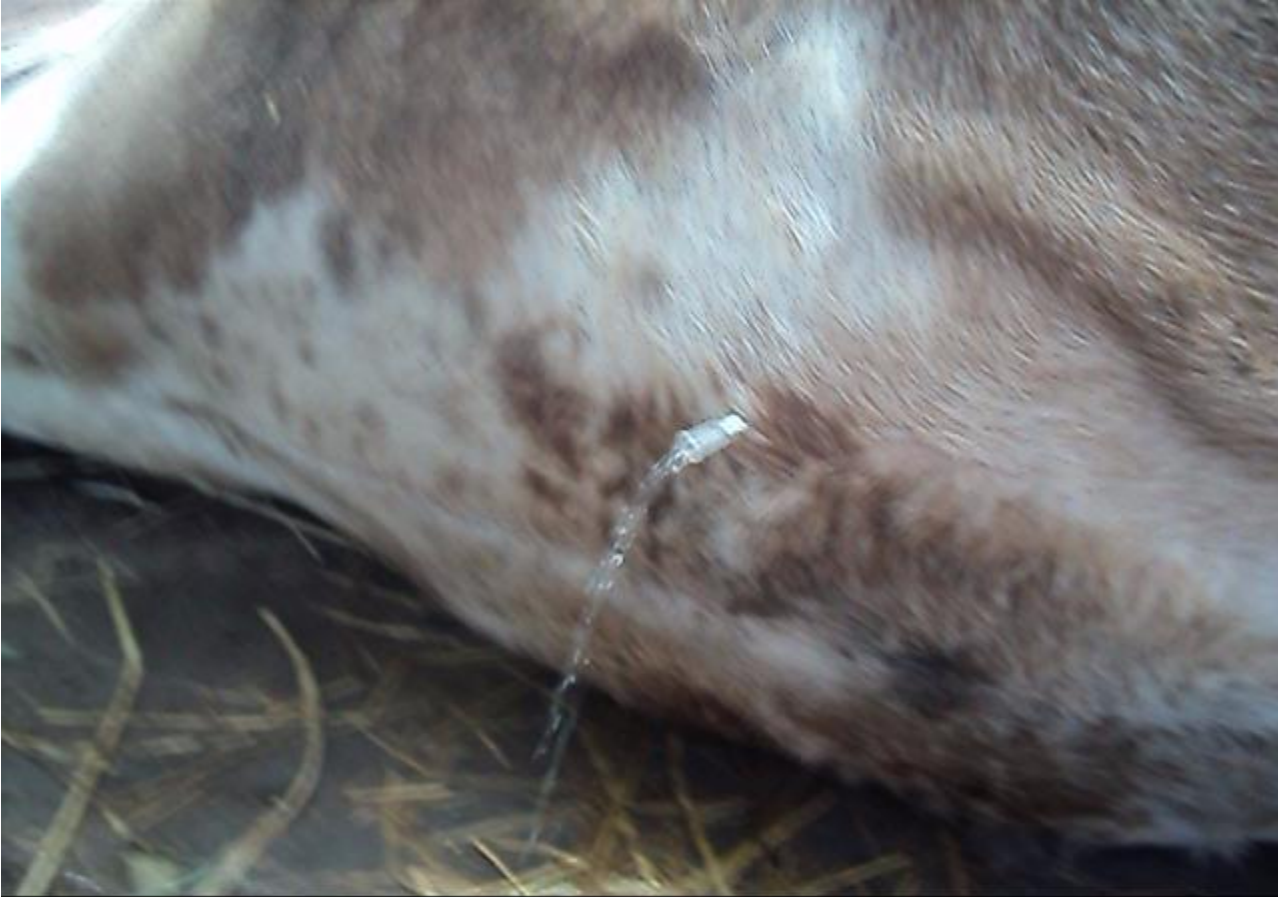
Dr.S.Sivaraman

ABDOMINOCENTESIS



Dr.S.Sivaraman





Dr.S.Sivaraman

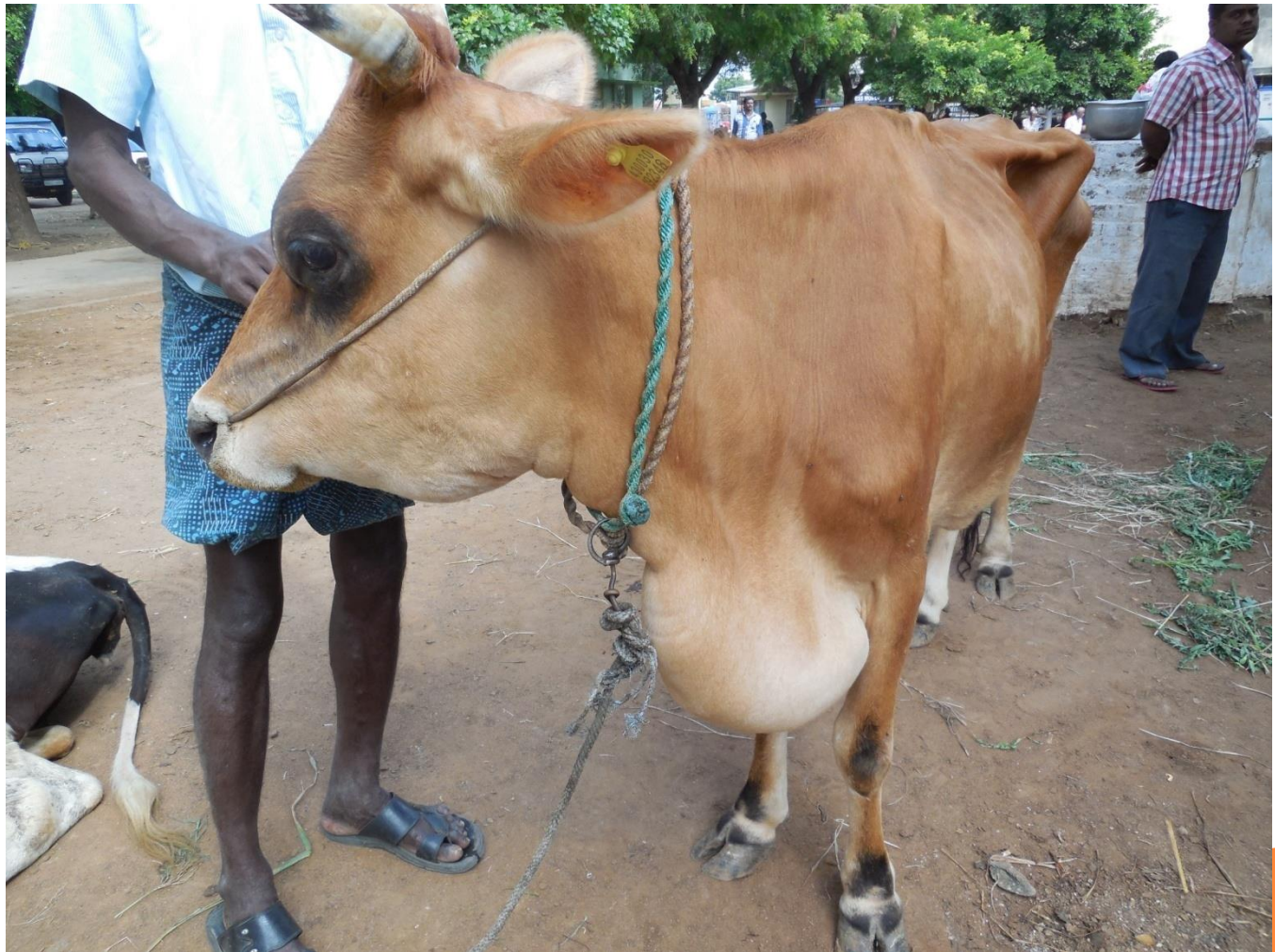

Traumatic Pericarditis



Dr.S.Sivaraman

Pericarditis



Dr.S.Sivaraman

PERICARDIOCENTESIS



Dr.S.Sivaraman





Dr.S.Sivaraman

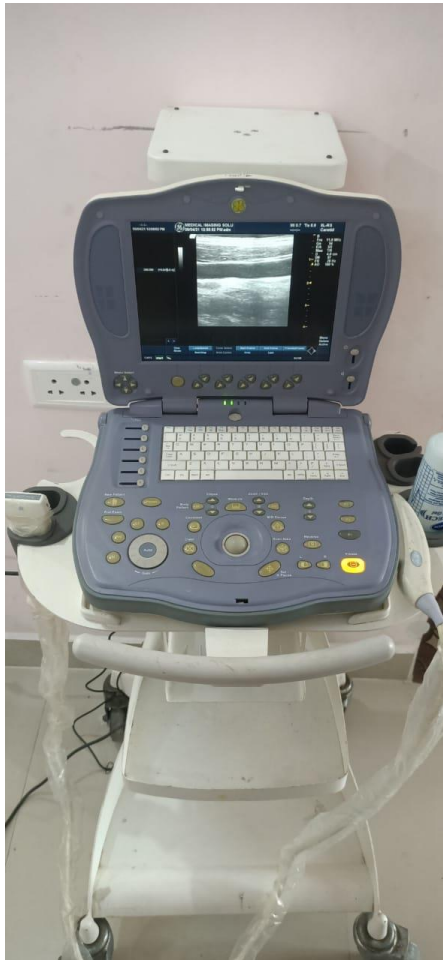



Dr.S.Sivaraman



ULTRASOUND



Dr.S.Sivaraman



ENDOSCOPY



Dr.S.Sivaraman



BORESCOPE



Dr.S.Sivaraman

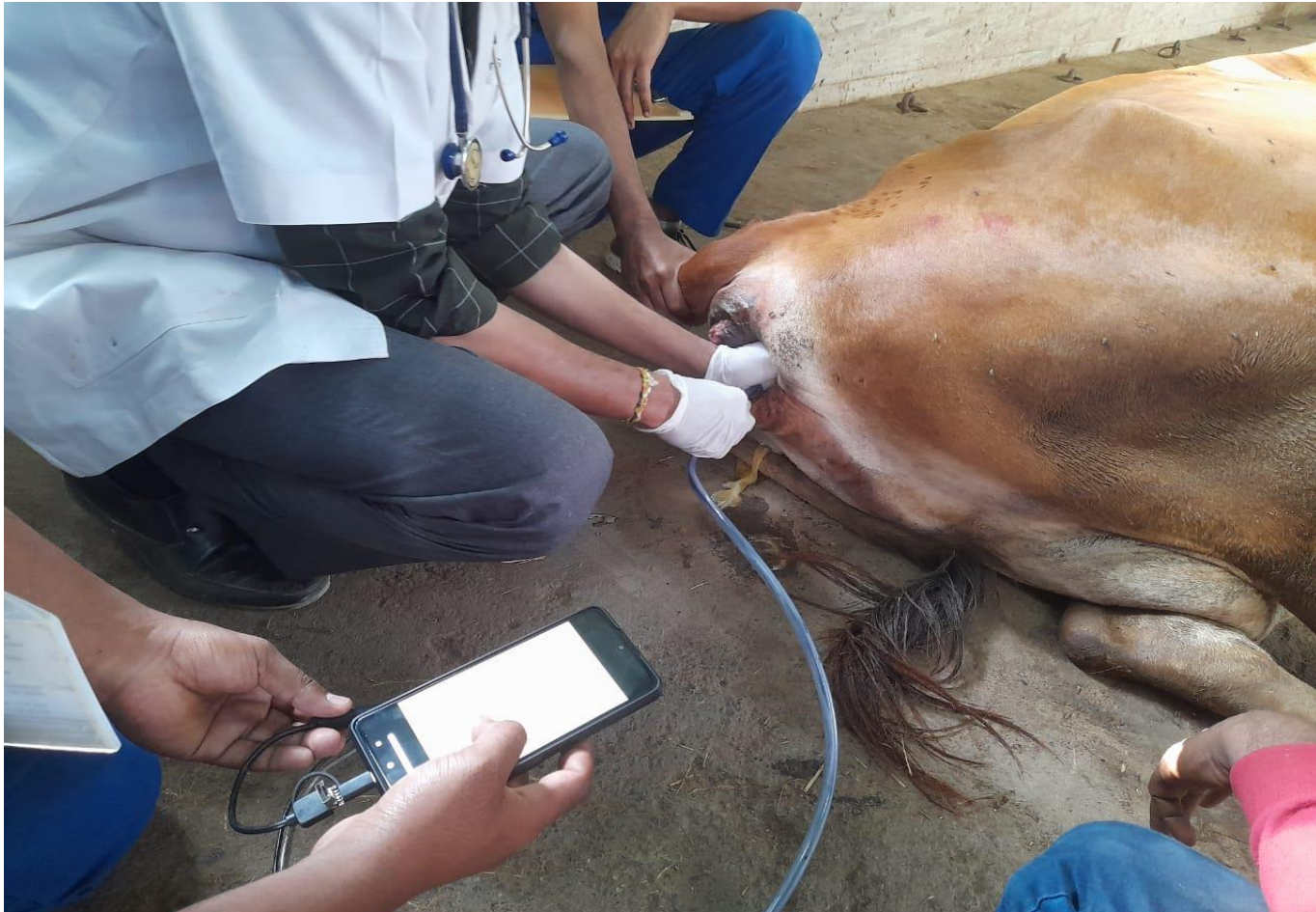

BORESCOPE



Dr.S.Sivaraman





Dr.S.Sivaraman





Dr.S.Sivaraman



Every thing is
possible in our
field Practice

Dr.S.Sivaraman



THANK YOU



Dr.S.Sivaraman

